

INTRODUCTION

Wullstein and Zollner introduced the concept of tympanoplasty in the field of chronic ear diseases. Lempert originally designed tympanomeatal flap for his tympanosympathectomy operation. Later adopted by Rosen for operation on the stapes. The concept of placing the graft under the drum remnant was set forth by Shea and Tabb in 1960's.

Their procedure were identical but they employed vein as a graft material. The technique was same as in stapedectomy to raise the endomeatal flap and place the graft under it.

Maurice Sourdille innovation of using tympanomeatal flap for tympanoplasty was the starting point of new era of modern tympanoplasty. Since then tympanomeatal flaps have been useful in underlay tympanoplasty and other Otologic surgery.

The elevated tympanomeatal flap allows access for a number of middle ear procedures like repair of TM or perilymph fistula, ossiculoplasty,

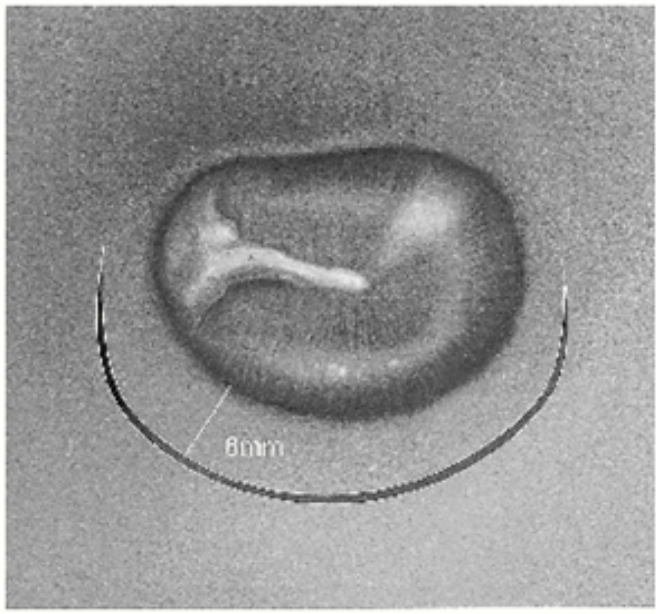
remove growths such as cholesteatoma and glomus tumour.

Different types of tympanomeatal flap are named as per the base of the flap:

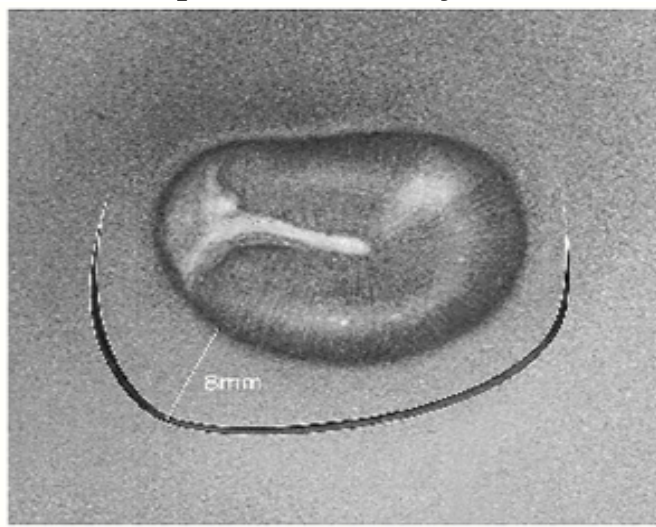
- 1. Superior Flap.(Plester, Sheehy and Glasscock)**
- 2. Anterior Flap.(Shambaugh,Singh et al)**
- 3. Inferior Flap.(Seifi AE)**
- 4.Anterior and posterior Flap. (Gibb and Chang)**
- 5.3 Flap technique (Roy Chaudri)**
- 6.Vascular strip was another name given to the superiorly based flap.**

Balkan et al in 2003 named these flaps with some minor variations

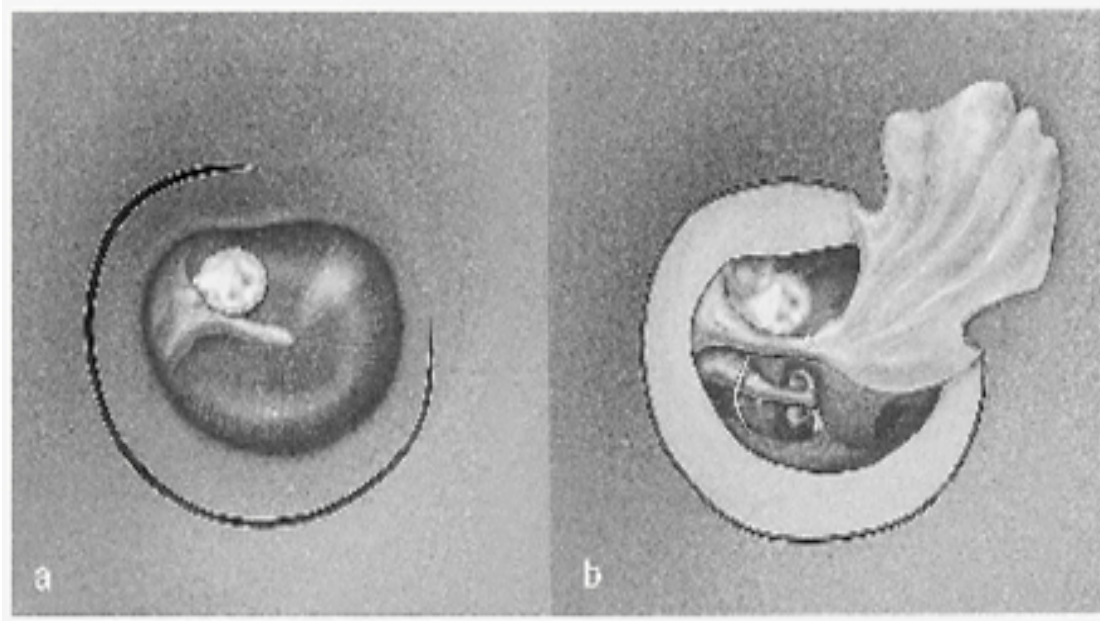
- 1. Standard Flaps**
- 2. Stapedectomy Flap**
- 3. Congenital Choleateatoma Flap**
- 4. Glomus tympanicum Flap**



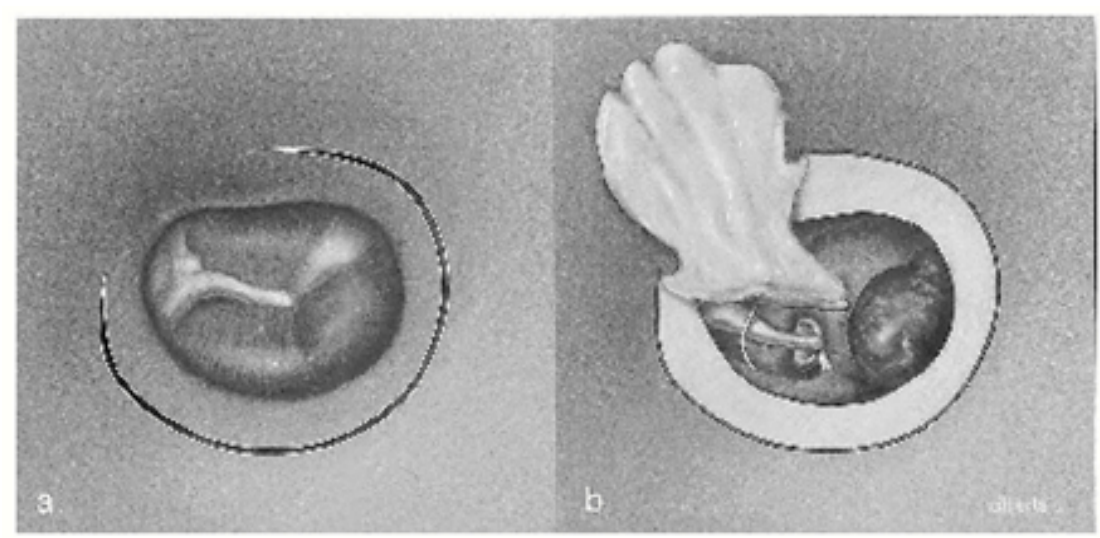
Standard flap has many uses and provides maximum exposure to the posterior mesotympanum. The incision extends to 12 o'clock and 6 o'clock positions and is kept 1 mm away from the tympanic membrane

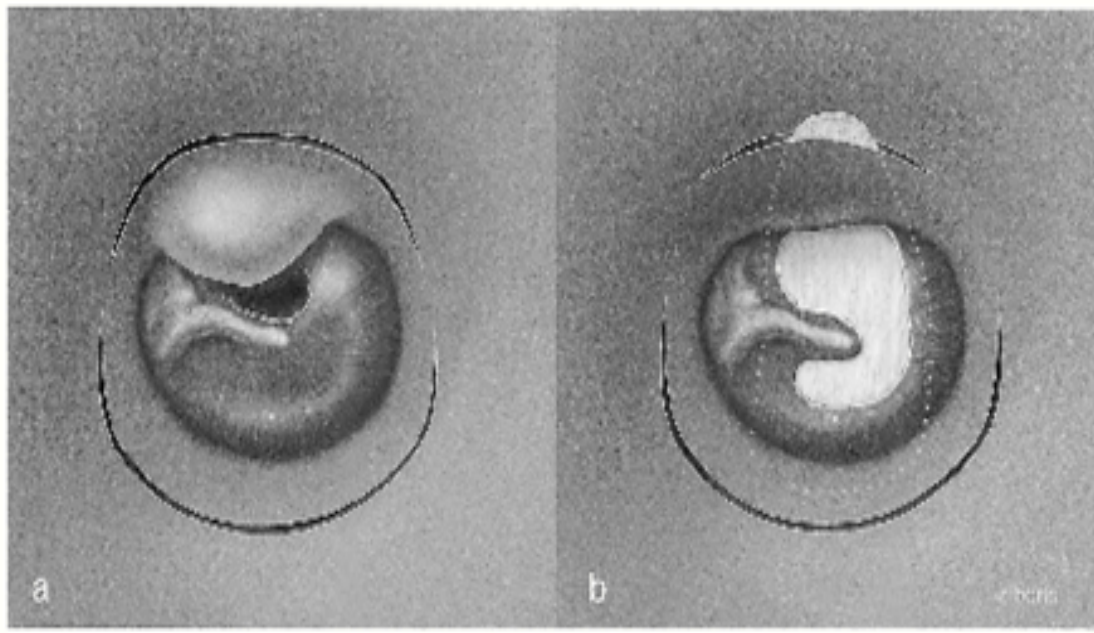


Stapedectomy or ossicular reconstruction flap. In the Minor variation of the standard flap, an asymmetrical incision is made With the superior portion of the flap being 8 mm long to compensate for curettage of the scutum.



Congenital cholesteatoma flap. The flap extends to the standard flap to provide better access to the anterior and superior mesotympanum (A). The most common location of small congenital cholesteatomas is shown (B).





Anterior canal wall flap. A limited anterior flap may be used to pull a graft through, to stabilize it for anterior marginal perforations (A). The flap may be extended on the anterior wall to remove canal wall bulge, osteoma, or exostosis(B)

Tears in T-flap do occur while elevating the flap. Most commonly tears occur in the hand of inexperienced Otologic surgeons but can also occur in experienced hands.

With the above reference, we designed a prospective study to see whether the tear which usually occurs during elevation of the flap really matters or not ? This study is first of its kind in the literature.

Material and Methods:

Patient data included:

- 1. Age**
- 2. Sex**
- 3. Audiogram**
- 4. Significant medical problems**

All ears were dry 3-4 weeks prior surgery.

Age range from 15-55 years.

All cases underwent audiological and evaluation before surgery

Approach: All cases underwent post aural approach with underlay technique. A Prospective study for a period of 18 months from July 2014 till December 2015. Done in Buraidah Central Hospital. 70 cases of CSOM who underwent type I tympanoplasty by underlay technique were studied during this period.

Inclusion criteria:

CSOM of safe type with medium size; kidney shape, subtotal or total perforation.

Exclusion criteria:

- 1.CSOM with cholesteatoma / polyp / granulation**
- 2.Marginal perforation**
- 3.Small perforation which can be dealt with permeal approach.**

All cases went under the procedure through post aural approach. Total 14 cases had tear in the tympanomeatal flap, during elevating the flap.6 Cases had small tears linear or button hole type, which did not need any repair. Only gelfoam piece was kept over the tear. 8 Cases had large tears that were repaired by the help of TMF graft covering the perforation as well as the tear below the tympanomeatal flap, The torn flap was approximated over the graft and gelfoam was kept over it so as to stabilize it. ONE Case had a very thin tympanomeatal flap where elevation was difficult and nearly

had total tear in the flap.This was corrected by large TMF covering the bare area of the bone totally in the EAC.

Results:

6 cases with small linear and button hole tear healed without any repair.

7cases with large tear healed with delayed process, out of which 1 case had posterior perforation in long term follow up.

1 case with nearly total tear healed completely with the TMF graft, it took some more time to heal as compared to the above cases.

Failure rate was 7.2% out of 14 tears.

Technique –used was Underlay

Post auricular incision

Harvest graft

Perforation edges

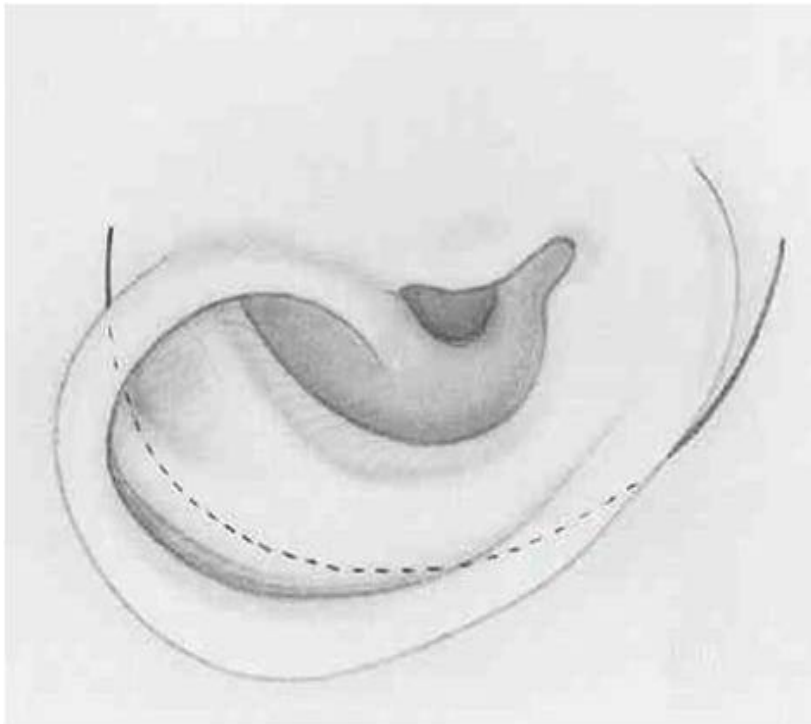
Elevation of tympanomeatal flap

Annulus

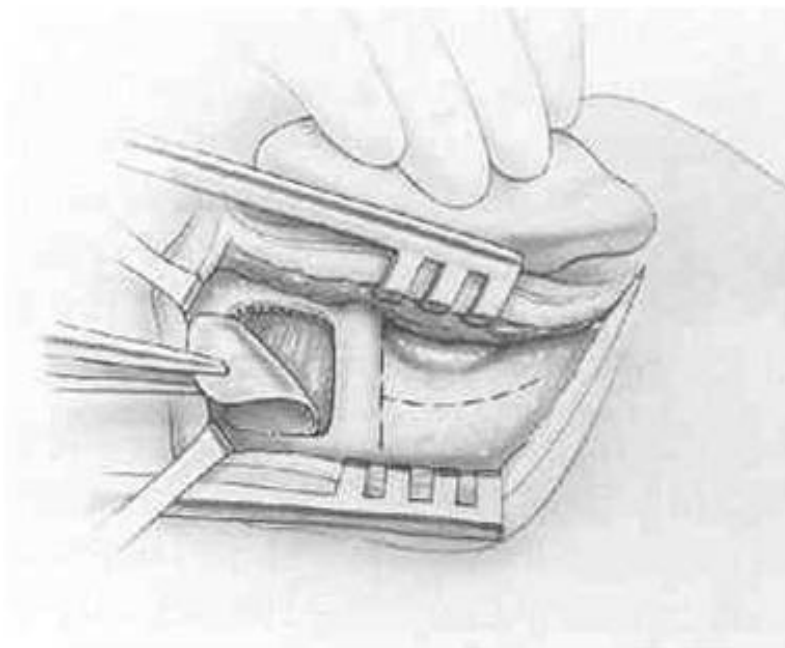
Gelfoam

Graft placement underlay

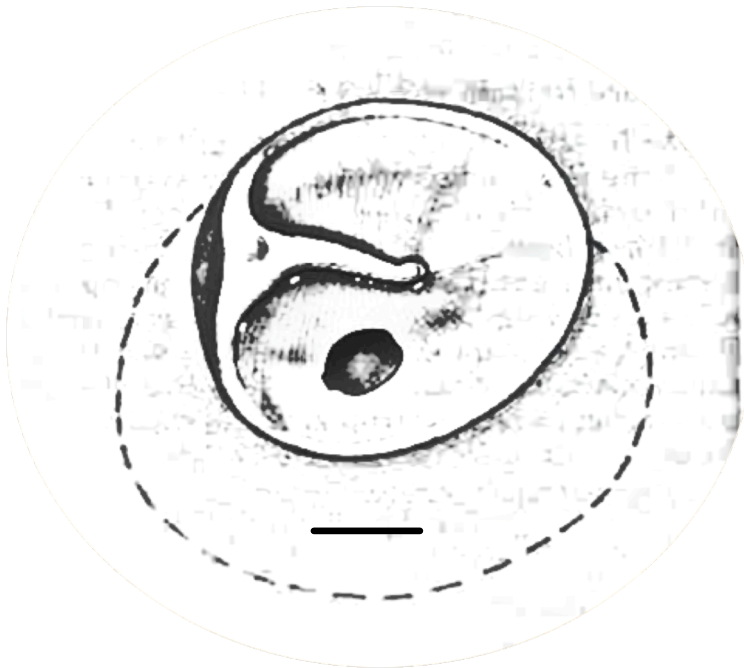POST AURICULR INCISION



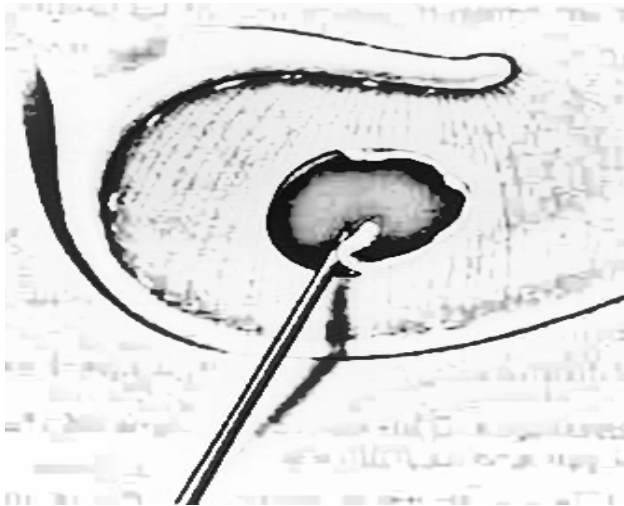
HARVESTING THE TMF GRAFT



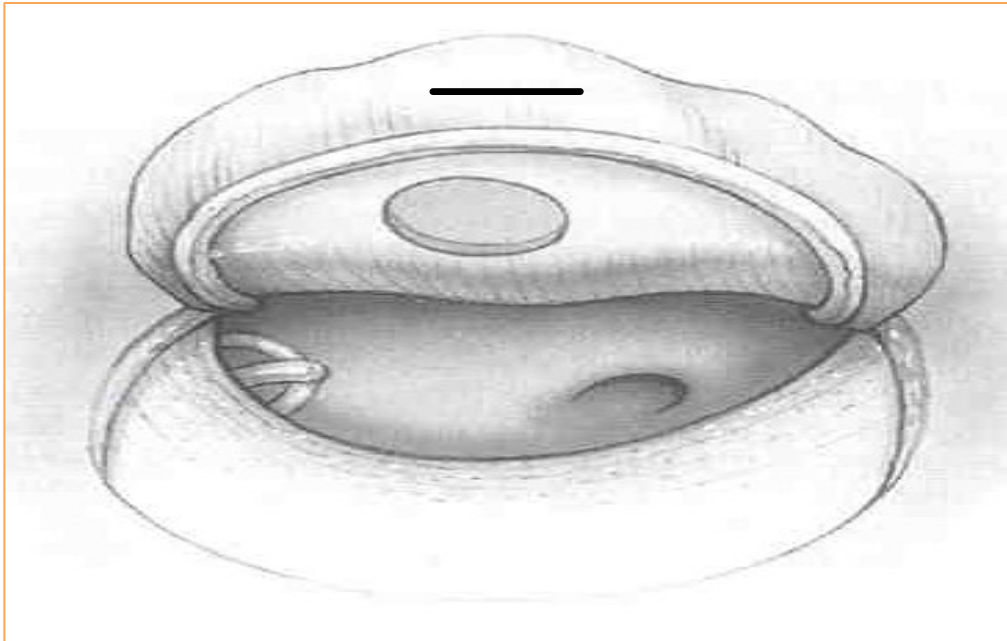
LINEAR TEAR IN THE TMFLAP



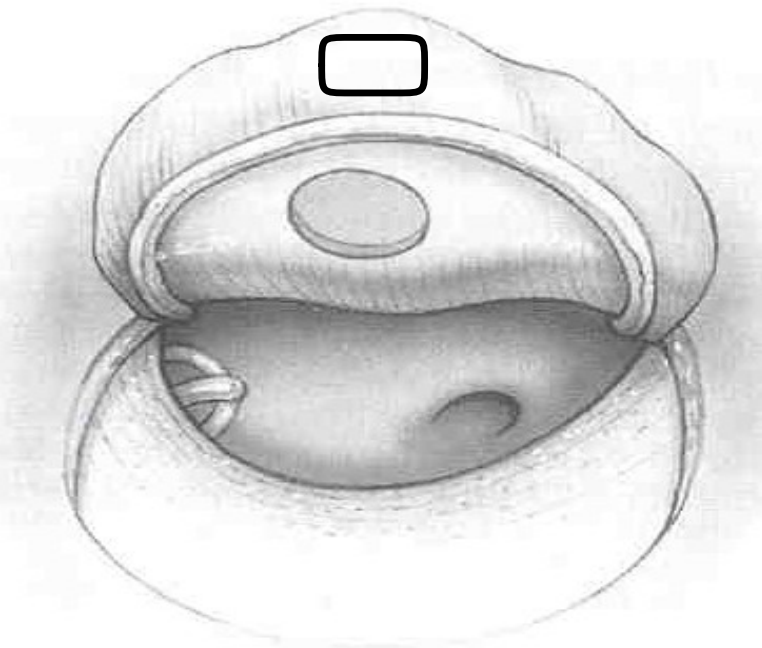
FRESHENING THE MARGINS



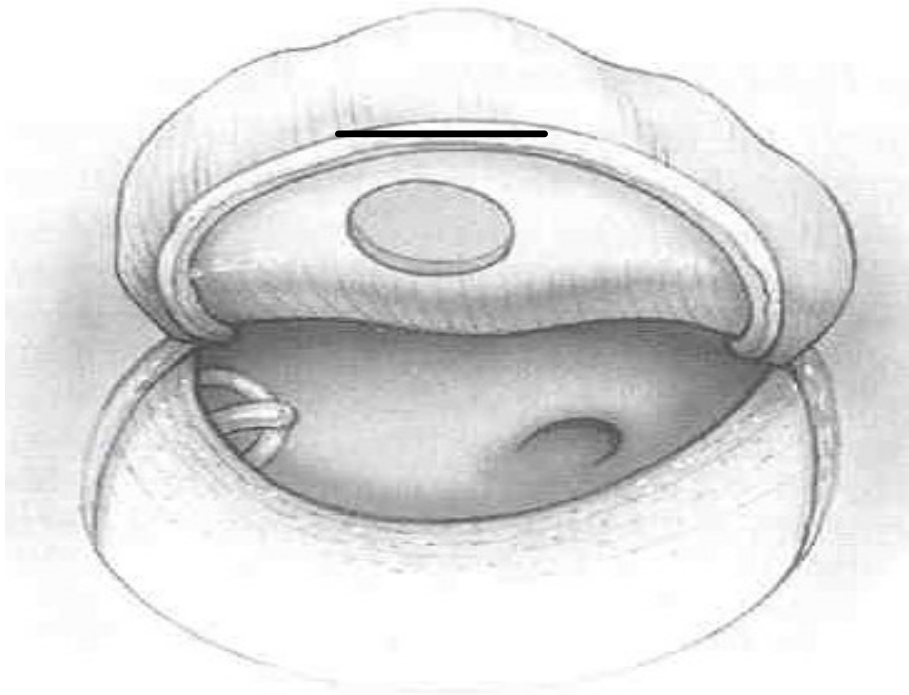
LINEAR TEAR IN TMFLAP



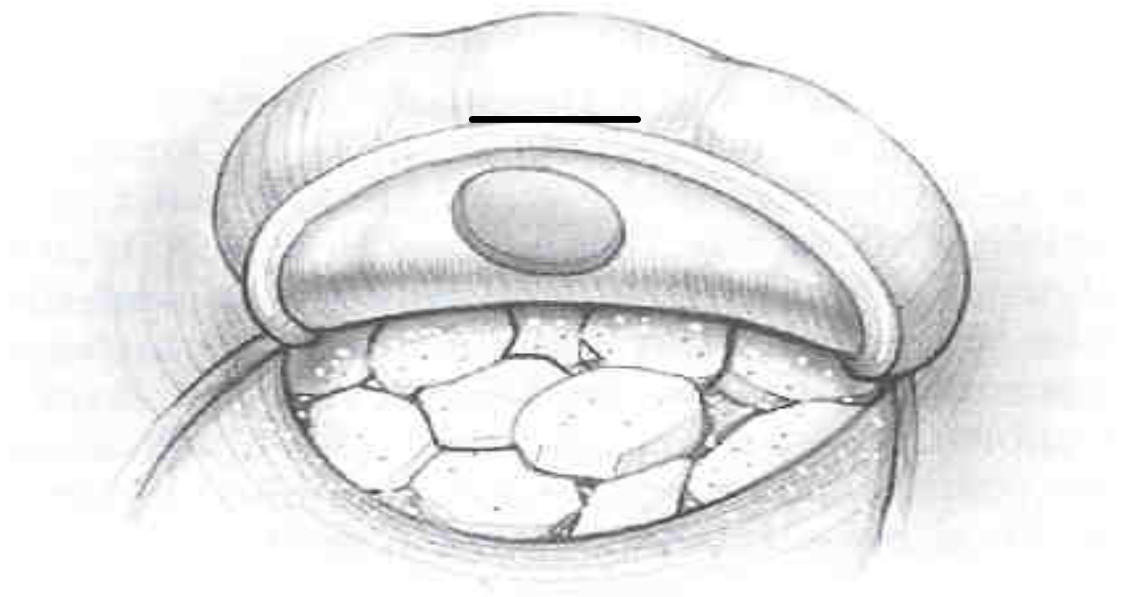
BUTTON HOLE TEAR IN THE TMFLAP



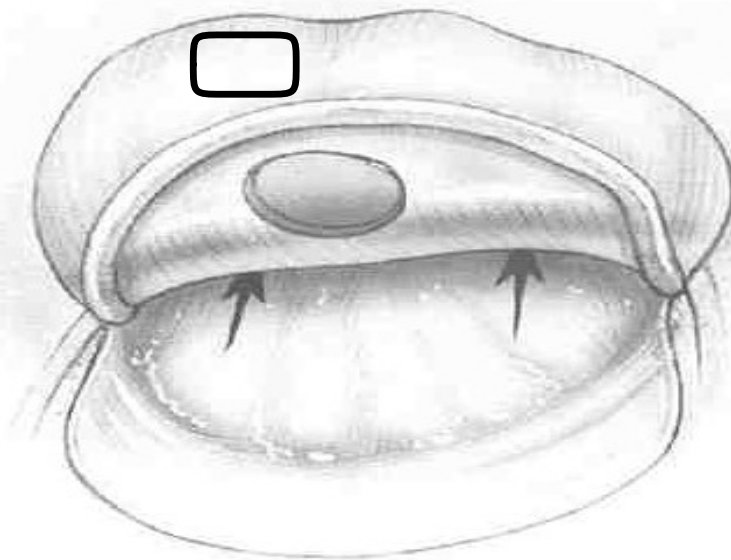
TEAR IN THE ANNULUS



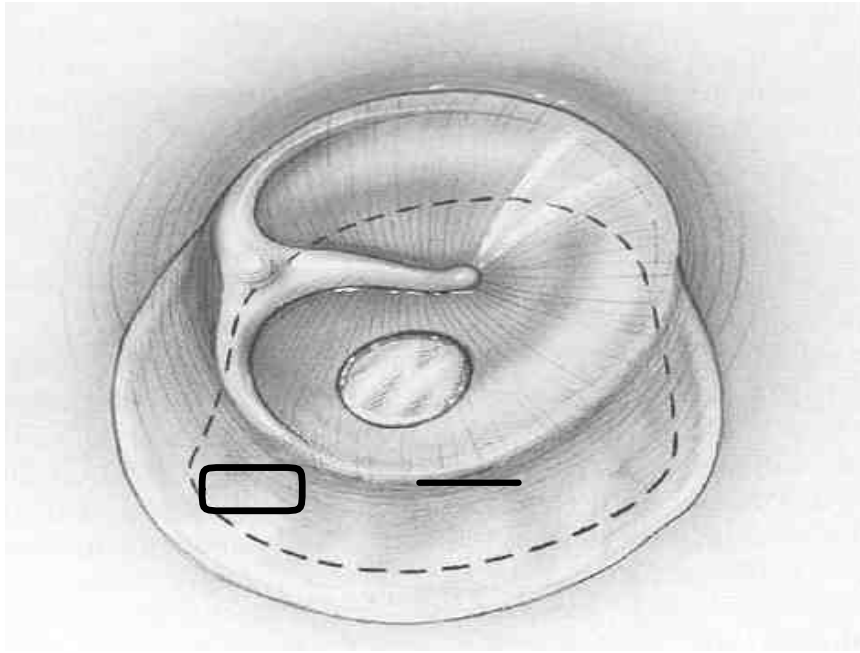
TEAR IN THE ANNULUS



GRAFT PLACED IN THE UNDERLAY
TECHNIQUE



UNDERLAY GRAFTING COVERING THE TM
DEFECT AND THE DEFECT IN TMFLAP



DISCUSSION:

Elevation of tympanomeatal flap (T-flap) is an important step in underlay tympanoplasty. Raising the T-flap is the state of the art knowledge. The goal of elevation T-flap is to expose the ME with elevation TM and mobilise the skin from the groove without damaging it so that ME can be extraordinarily exposed

Concept of underlay tympanoplasty after elevation of T-flap was set forth by *Shea* and *Fabb* in 1960. Innovation of using

tympanomeatal flap in tympanoplasty by *Maurice Sourdille* gave a new turn to tympanoplastic procedure.

Tears in T-flap can occur while elevating the flap at different sites:

- 1.Oblique *tympanomastoid suture* line**
- 2.Elevation at the of *annulus* where the tear is very common in experienced hands.**
- 3.Tear can occur while *drilling* with cutting burrs in the canal**

Tears in the tympanomeatal flap may occur in following ways:

- 1.A *linear* or *button* perforation may occur in the skin flap**
- 2.The skin flap may separate from the *tympanic annulus*. This usually occurs in inferior location and is due to failure to elevate the tympanic annulus from its sulcus**

Tears in the TM-flap or TM that occurs during elevation of the flap and drum should be repaired at the completion of the procedure. Repair of the tears in the T-flap is simple but meticulous.

Linear and button hole tears need no repair, care must be taken to avoid unfolding the margins of tears while replacing the flap.

Smaller tear near the annulus require no repair if it is approximated properly while replacing the flap. Tears in the TM-flap can be repaired by different materials like fat, vein, perichondrium and TMF graft. It depends upon which material is readily available for repair.

During stapedectomy fat and perichondrium are used very commonly. During tympanoplasty TMF graft is used very commonly as its access is at the same incisional site.

Today TMF has become very common in the repair of tear in TM-flap during tympanoplastic procedure.

It has been shown by experience that TM-flap tear can be avoided by never taking the knife of the bone surface.

If one always keeps the knife on the bone surface one can develop the separation/elevation on a relatively broad front. Secondly never allow soft tissue beneath the knife. With these

precautions one cannot perforate the T-flap

CONCLUSION

We conclude that tears in the T-flap are not hazardous events, they should be handled carefully with patience and repaired by a proper technique at the end of the procedure.

Different materials like fat, vein, perichondrium and TMF grafts can be used in repair process

The study was aimed to give message, mainly to the learners and inexperienced otological surgeons :

A torn tympanomeatal flap does not need abandoning the procedure, it can be repaired by approximation or with the help of temporalis fascia graft

placement over the bare area of the bony canal.